

The Tumor Detection Neural Network using Texture Features

Mira Parmar,
ME EXTC, FCRIT,
Vashi, Navi Mumbai, India

Mrs. Sadhana Pai
Associate Professor,
EXTC, FCRIT,
Vashi, Navi Mumbai, India

Abstract: Magnetic Resonance Imaging (MRI) is a medical imaging technique which provides information about the human tissue anatomy. The MRI images are high in tissue contrast which helps the radiologist to visualize the finer details of the most delicate parts of the body such as brain. Because of the variety of shapes, locations and image intensities within the MRI, it becomes the challenging task for the radiologists to diagnose the brain tumor correctly at its early stage. In this paper, a Tumor Detection Neural (TDN) network has been developed which detects whether the MRI for test is having benign or malignant tumor. First the tumor region is extracted using the image processing techniques which enhance the image and removes the skull region of the image. Then the texture features of the image are extracted using the Gray Level Co-occurrence Matrix (GLCM) with which the TDN network is trained. On basis of the training, the TDN network displays a message whether the test image is having a benign or malignant tumor.

Keywords: Brain tumor, Magnetic Resonance Imaging (MRI), Gray Level Co-occurrence Matrix (GLCM), Neural Network

1. INTRODUCTION

A tumor is a mass of tissue that grows out of control of the normal forces that regulates growth. The tumor not only destroys the healthy tissues but also produce some adverse effects such as inflammation, brain swelling and pressure within the skull. Human brain tumors are complex and the accurate diagnosis of these tumors is essential in order to provide a prognosis of tumor development [1].

Brain tumors can be categorized into two main types which are benign and malignant tumors. Benign tumors have cells that do not invade the tissues around them and do not spread to other parts of the body. Benign tumors have clear borders or edges and is sometimes life threatening. Malignant tumors are usually more serious. They grow more rapidly and invade the surrounding healthy brain tissue.

According to the symptoms, to identify the internal body abnormalities the doctors would ask the patient to undergo several tests. Most commonly Computed Tomography (CT) and Magnetic Resonance Imaging (MRI) are used to locate brain tumor. The information from the MRI images obtained will decide the type of treatment a patient would be given [2]. Perhaps the most widely used clinical diagnostic and research technique is MRI. MRI is an

efficient medical imagery tool based on the principal of nuclear magnetic resonance (NMR). The MRI images may contain some noise and sometimes text too. So there is a need in pre-processing these images to enhance them. The image processing algorithms for enhancement such as histogram equalization are used. To extract the tumor region the skull border of the MRI is removed. The feature extraction means to get the information of image in the form of numerical data. This data extracted gives the information of the property of the texture character. Texture features are obtained with the Gray Level Co-occurrence Matrix (GLCM). The GLCM is a tabulation of how often different combinations of pixel brightness values or the grey levels occur in an image. The texture features extracted are the contrast, correlation, energy, homogeneity, dissimilarity, entropy and maximum probability. These seven features serves as inputs to the neural network.

Artificial Neural Network (ANN) is highly interconnected network of a large number of processing elements called neurons. This network is inspired by the brain. They exhibit mapping capabilities or pattern association and learn by examples. Back propagation is a systematic method of training multilayer artificial networks built on high mathematical foundations and has very good application potential [8].

The aim of this paper is to extract the tumor region and determine its texture features with the help of which the TDN network determines the type of the tumor. The MRI image of different type of brain tumor forms the database which is store in the knowledge base for this project.

2. METHODOLOGY

The TDN network developed for tumor detection is a feed forward backpropagation neural network. The knowledge base is made of 50 MRI images having benign or malignant tumors. The block diagram of the TDN network is shown in figure 1.

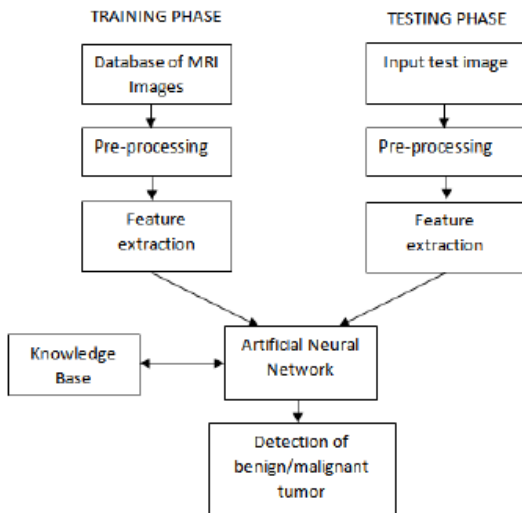


Figure 1: The TDN network

In the training phase, all the images of knowledge base go through various processing steps. The steps are image preprocessing to enhance the image, labeling connected components of image to extract the tumor region and calculate GLCM features for extracting texture features of image. The TDN network is trained with these extracted GLCM features as its input. After the training is done the TDN network can simulate the output for any given MRI image for test.

In the testing phase, an unknown MRI image with tumor is given for test. This test image is pre-processed to extract the tumor region and its texture features are extracted using the GLCM. The TDN network compares these features with the features of the images of the knowledge base. On the results of comparison, the network displays a message whether the input image is having benign or malignant tumor.

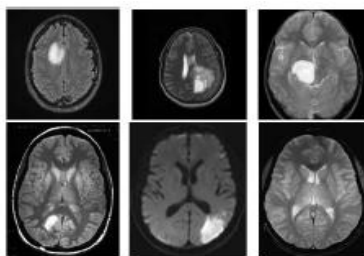


Figure 2: Abnormal MRI brain images

Asymmetry in an axial MR brain image strongly indicates abnormality. Hence symmetry in axial MR images is an important feature that needs to be considered in deciding whether the MR image at hand is of a normal or an abnormal brain. The abnormal T2-weighted MR images are shown in figure 2. The lack of symmetry in an abnormal brain MR image is clearly seen in the images.

3. IMPLEMENTATION RESULTS

The implementation is done in three steps, namely image preprocessing, extraction of tumor region, texture feature extraction and finally the neural network. The following sections show the results obtained while implementing these steps.

3.1 Image Pre-processing

The TDN network is trained for 50 MRI images. Out of which 25 are with benign tumor and other are with malignant tumor. One of the images with malignant tumor is shown in figure 3.

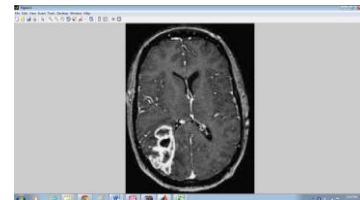


Figure 3: MRI image with tumor

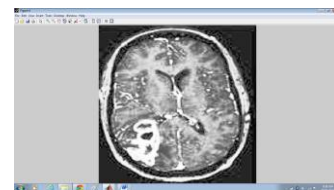


Figure 4: Resized and histogram equalized image

The MRI is converted to grayscale if it is colored. Then it is resized to 210 X 210 so that all images will have same size. The contrast of the image is enhanced with the histogram equalization. The result of this operation is shown in figure 4.

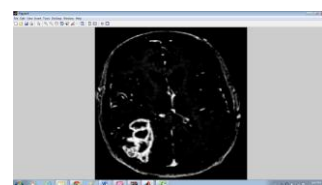


Figure 5: Intensity mapped image

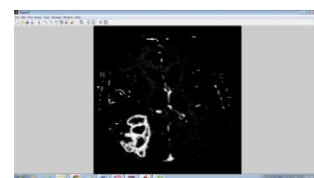
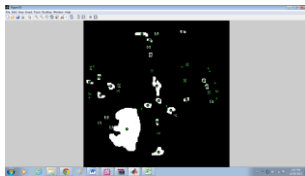


Figure 6: Skull removed image

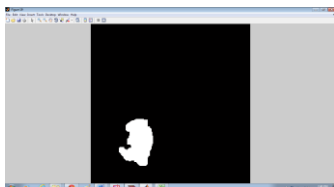
The intensity adjustment of the image is done using the intensity mapping operation. The gamma value is kept greater than 1 so that the intensity mapping of the image is done towards the darker side. This is shown in figure 5. The skull is removed so that the extraction of tumor region can be done. The figure 6 shows the image after the skull.

For further operation this image is needed to be converted into a binary image. The threshold for binarisation is decided using the Otsu's thresholding method. The output of binary image is shown in figure 7.

The connected components of the binary image are labeled using 8-connectivity. Then the centers of mass of labeled region are marked to know the position of labeled components.



A white image is taken and the labeled regions are made black in it. Then this white image and the binary images are logically ANDed so that the unwanted regions other than the tumor are removed. This step of is repeated till the image is left with the tumor region. The figure 9 is the white image with labeled regions made black and the figure 10 is the result of ANDing the white image and the binary image.



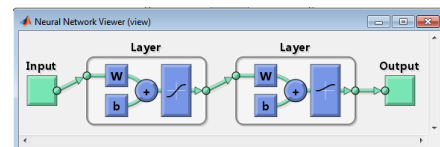
The screenshot displays the Microsoft Excel 2010 interface. The title bar indicates the file is 'Excel2012 - Microsoft Excel 2010 - Kanton.pptx'. The ribbon at the top shows the 'Formulas' tab selected, with the 'Calculation Options' group expanded to 'Automatic'. The main workspace contains a data table with 10 columns (A-J) and 20 rows (1-20). The data is as follows:

	A	B	C	D	E	F	G	H	I	J
1	1.008	0.978	0.988	0.975	0.975	1.008				
2	0.985	0.962	0.983	0.966	0.933	0.954	0.943	0	1	
3	0.982	0.942	0.942	0.942	0.942	0.942	0.942	0.942	0.942	0
4	0.943	0.919	0.943	0.957	0.948	0.948	0.948	0.948	0.948	0
5	0.976	0.971	0.986	0.966	0.962	0.976	0.976	0.976	0.976	0
6	0.906	0.884	0.949	0.905	0.945	0.916	0.974	0	1	
7	0.983	0.988	0.988	0.983	0.983	0.983	0.983	0.983	0.983	0
8	0.933	0.908	0.985	0.901	0.978	0.948	0.942	0.942	0.942	0
9	0.927	0.949	0.958	0.959	0.987	0.927	0.927	0.927	0.927	0
10	0.956	0.947	0.912	0.927	0.929	0.939	0.954			
11	0.985	0.914	0.947	0.957	0.976	0.971	0.976	0.976	0.976	0
12	0.946	0.986	0.979	0.971	0.979	0.946	0.986			
13	0.961	0.933	0.934	0.962	0.987	0.966	0.955	0	1	
14	0.961	0.934	0.923	0.951	0.961	0.951	0.955	0.955	0.955	0
15	0.923	0.951	0.887	0.906	0.981	0.931	0.977	0.977	0.977	0
16	0.987	0.988	0.962	0.906	0.997	0.982	0.982	0.982	0.982	0
17	0.982	0.985	0.985	0.987	0.982	0.984	0.978	0.978	0.978	0
18	0.983	0.983	0.984	0.986	0.947	0.986	0.986	0.986	0.986	0
19	0.985	0.985	0.986	0.987	0.976	0.983	0.983	0.983	0.983	0
20	0.906	0.949	0.958	0.961	0.961	0.946	0.946	0.946	0.946	0
21	0.945	0.967	0.963	0.972	0.934	0.936	0.945			
22	0.937	0.937	0.949	0.939	0.943	0.943	0.943	0.943	0.943	0
23	0.916	0.919	0.977	0.926	0.980	0.976	0.963	0.963	0.963	0
24	0.968	0.975	0.939	0.966	0.969	0.947	0.947	0.947	0.947	0
25	0.951	0.917	0.958	0.936	0.993	0.946	0.987	0.987	0.987	0
26	0.965	0.959	0.967	0.951	0.953	0.963	0.963	0.963	0.963	0
27	0.999	0.983	0.978	0.980	0.918	0.977	0.963	0.963	0.963	0
28	0.944	0.939	0.947	0.906	0.949	0.938	0.937	0.937	0.937	0
29	0.981	0.983	0.936	0.933	0.984	0.978	0.945	0.945	0.945	0
30	0.947	0.952	0.917	0.909	0.981	0.958	0.953	0.953	0.953	0

The status bar at the bottom shows 'Formulas' and '100%' zoom.

The features extracted from the above image of figure 11 are stored in the excelsheet which is shown below. The first seven columns of the excelsheet shown in figure 12 are the seven GLCM features and the last two columns are the targets. The targets for these images are [0 1] if there is benign tumor and [1 0] if there is malignant tumor.

The feed forward backpropagation network is made which is named as Tumor Detection Neural (TDN) network. The inputs to this network are the GLCM features of the 50 images that form the knowledge base.



The TDN network has seven inputs as GLCM features and two hidden layers. The first hidden layer consists of 21 neurons and the second hidden layers consists 2 neurons. According to the texture features extracted of the knowledge base, the TDN is trained to decide whether an input image for test is having benign or malignant tumor. As shown in figure 14, the detection done by the TDN network is displayed in the form of message box.

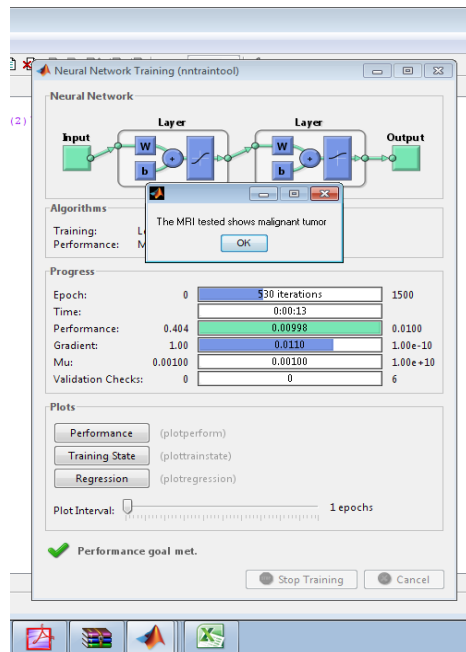


Figure 14: The message displayed by TDN network

4. RESULTS FOR THE TESTING PHASE

After training phase, the TDN network is given some other MRI with tumor for testing. In the testing phase, the network tests MRI and compares the features of the test image with the features of the images of the knowledge base. On the results of comparison, the network displays a message whether the input image is having benign or malignant tumor. The results are given in below in form of table 1. The results in the table are for four images taken from the Harvard medical school website where they provide the MRI for brain diseases. In this way more MRI images can be tested using the TDN network.

The result of the result is displayed on the Graphical User Interface (GUI). The GUI for the TDN network is shown in figure 15. It has four components namely Read Test MRI, Extract Tumor, Area of Tumor and the Test Result.

The TDN network first takes the MRI image for test. The Read Test MRI pushbutton displays the image that has to be tested by the TDN network. The second pushbutton on the GUI named as Extract Tumor displays the extracted tumor region. The area of the tumor is displayed in the message box with the pushbutton named as Area of Tumor. The message is displayed as "Area= ". The result of the test is displayed with the pushbutton named as Test Result. The result for the given test image is displayed in the message box as "The MRI tested shows malignant tumor". The GUI displayed in figure shows the result of the test done by the TDN network.

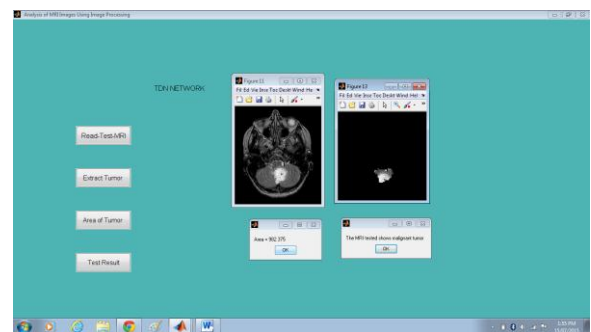


Figure 15: GUI displaying the test results


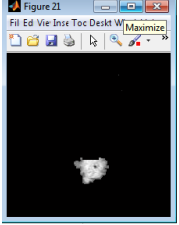

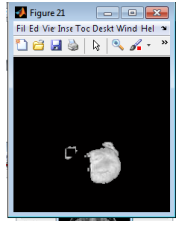

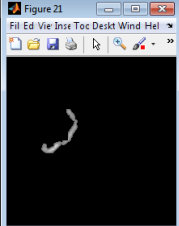


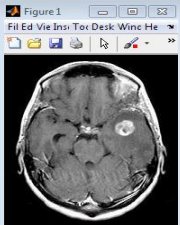
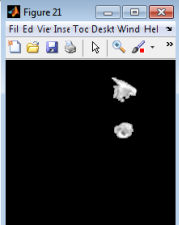
Data from the internet			Results obtained from the software		
MRI No	The type of brain disease detected	MRI image for test	Tumor region	Area of tumor	Type of tumor detected
1	Metastatic adenocarcinoma which is one type of malignant tumor			985.7500	malignant
2	Glioma which is one type of malignant tumor			2010	malignant
3	Metastatic bronchogenic which is one type of benign tumor			512.8750	benign
4	Sarcoma which is one type of malignant tumor			2.2296e+003	malignant
5	Metastatic bronchogenic which is one type of benign tumor			952.3750	benign

Table 1: Results for the test images

5. CONCLUSION AND FUTURE SCOPE

The TDN network has two hidden layers. The number of neurons in the first layer is 21 and for the second layer the number of neurons (H) is 2 for two outputs 0 and 1. It is observed that the number of neurons has to be more than the number of inputs. For the TDN network the number of inputs i.e the texture features are 7. The numbers of neurons are in multiples of the number of inputs. It can be concluded that by selecting the number of neurons as approximately three times the texture features and the training sample size or the number of MRI images in the knowledge base as 50, good percentage of correct classification or accuracy of 87.5% is achieved.

In this project, the area of the extracted tumor region has been calculated. The network can be made more efficient if both the area and volume of the tumor are obtained. This requires all the scanned MRI slices of the whole brain and a software which produces the three dimensional view of the tumor present in the brain. In the testing phase, every time when a new MRI image is tested its features can be added to the knowledge base. This would result in wide varieties of tumor included in the knowledge base for detection. This would also increase the size of training samples required to train the neural network and increase the accuracy of the network.

REFERENCES

1. https://en.wikipedia.org/wiki/Medical_imaging
2. <http://www.iss.infn.it/topem/PET-MRI/mri-general.pdf>
3. <http://www.urmc.rochester.edu/encyclopedia/content.asp>
4. Rohini Joseph, Senthil Singh and Manikandan, "Brain tumor MRI image segmentation and detection in image processing" IJRET International Journal of research in Engineering and Technology
5. R. Gonzalez and R. Woods, Digital Image Processing, 3 Edition, Prentice Hall
6. Otsu, N., "A Threshold Selection Method from Gray-Level Histograms," IEEE Transactions on Systems, Man, and Cybernetics, Vol. 9, No. 1, 1979, pp. 62-66.
7. <http://www.fp.ucalgary.ca/mhallbey/tutorial.html>
8. Simon Haykin, Neural Networks and Learning Machines, 3rd edition, PH Learning Pvt Limited
9. K. S. Angel Viji and J. Jayakumari, "Automatic Detection of Brain Tumor based on Magnetic Resonance Image using CAD System with watershed segmentation" Proceedings of 2011 International Conference on Signal Processing, Communication, Computing and Networking Technologies (ICSCCN 2011)
10. Rajini, N.; Bhavani, R., "Classification of MRI brain images using k-nearest neighbor and artificial neural network," *Recent Trends in Information Technology (ICRTIT)*, 2011 International Conference on, vol., no., pp.563,568, 3-5 June 2011 doi: 10.1109/ICRTIT.2011.5972341
11. Noramalina Abdullah and Lee Wee Chuen, "Improvement of MRI Brain Classification using Principal Component Analysis" 2011 IEEE International Conference on Control System, Computing and Engineering
12. Rupsa Bhattacharjee and Dr. Monisha Chakraborty, "Brain Tumor Detection From MR Images: Image Processing, Slicing and PCA Based Reconstruction" 2012 Third International Conference on Emerging Applications of Information Technology (EAIT)