

# Review on Detection and Classification of Diabetic Retinopathy Lesions Using Image Processing Techniques

Manjiri B. Patwari  
Institute of Management  
Studies & Information  
Technology, Vivekanand  
College Campus,  
Aurangabad MS (India)

Ramesh R. Manza  
Dept of CS and IT, Dr.  
B. A. M.  
University,  
Aurangabad MS  
(India)

Yogesh M. Rajput  
Dept of CS and IT,  
Dr. B. A. M.  
University,  
Aurangabad MS  
(India)

Manoj Saswade  
Director, Saswade  
Eye Clinic”  
Aurangabad(MS)  
India (India)

Neha Deshpande  
Director”,  
Guruprasad Netra  
Rugnalaya pvt. Ltd,  
Aurangabad MS  
(India)

## I. INTRODUCTION

Diabetic retinopathy is one of the most common causes of blindness. However, efficient therapies do exist. An accurate and early diagnosis and correct application of treatment can prevent blindness in more than 50% of all cases.[1] Diabetic Retinopathy (DR) is the leading cause of blindness among working-age Americans. It is shown that early diagnosis and timely treatment could efficiently prevent visual loss. [2] Diabetic retinopathy (DR) is a common retinal complication associated with diabetes. It is a major cause of blindness in both middle and advanced age groups. According to the National Diabetes Information data (US). [3], Diabetic retinopathy (damage to the retina) caused by complications of diabetes, which can eventually lead to blindness. It is an ocular appearance of diabetes, a universal disease, which affects up to 80 percent of all patients who have had diabetes for 10 years or more. Although these intimidating statistics, research indicates that at least 90% of these new cases could be reduced if there was proper and alert treatment and monitoring of the eyes. The longer a person has diabetes, the higher his or her chances of developing diabetic retinopathy. In the United Kingdom everyone with diabetes aged twelve and above should be invited, at least annually, for retinal screening using digital retinal photography.[4] In diabetic retinopathy there are some diseases like, Microaneurysms, Microaneurysms are the first clinically detected lesions. It is tiny swelling in the wall of a blood vessel, It appears in the retinal capillaries as a small, round, red spot located in the inner nuclear layer of the retina. Hemorrhages, Hemorrhages are located in the middle layer of the retina. Retinal hemorrhage is the abnormal bleeding of the blood vessels in the retina. They have a ‘dot’ and ‘blot’ configuration. Cotton Wool Spot, Cotton wool spots are an abnormal finding on fundoscopic exam of the retina of the eye. They appear as fluffy white patches on

the retina. They are caused by damage to nerve fibers and are a result of accumulations of axoplasmic material within the nerve fiber layer. The nerve fibers are damaged by swelling in the surface layer of the retina. Exudates are yellow flecks are called hard exudates. They are the lipid residues of serous leakage from damaged capillaries. The optic disc or optic nerve head is the location where ganglion cell axons exit the eye to form the optic nerve. There are no light sensitive rods or cones to respond to a light stimulus at this point. This causes a break in the visual field called "the blind spot" or the "physiological blind spot".

**Table 1: Diabetic Retinopathy Lesion**

Sr . No	Diabetic Retinopathy lesion	Distinctive Ophthalmoscopic Features	Mechanism	Common Associated Conditions
1	Hard Exudate	Deep yellow with sharp margins, often circinate	Leakage from pre-capillary arterioles	Diabetes, hypertension, von Hippel Lindau disease, radiation
2	Cotton Wool Spot	Fluffy gray-white; usually near optic disc	Micro-infarction	Hypertension, diabetes, connective tissue disease, HIV
3	Microaneurysms	It is Tiny swelling in the wall of a blood vessel	Leakage from pre-capillary arterioles	Diabetes, hypertension, von Hippel Lindau disease, radiation
4	Haemorrhages	They are located in the middle layer of the retina	Leakage from pre-capillary arterioles	Diabetes, hypertension, von Hippel Lindau disease, radiation

Described the preliminary development of a tool to provide automatic analysis of digital images taken as part of routine monitoring of diabetic retinopathy in their clinic. Various statistical classifiers, a Bayesian, a Mahalanobis, and a KNN classifier were tested. The system was tested on 134 retinal images. The Mahalanobis classifier had the best results: microaneurysms, haemorrhages, exudates, and cotton wool spots were detected with a sensitivity of 69, 83, 99, and 80%, respectively. [1] a new spot lesion detection algorithm for retinal images with background diabetic retinopathy (DR) pathologies. The highlight of this algorithm is its capability to deal with all DR-related spot lesions of various sizes and shapes that is accomplished by a unique adaptive multiscale morphological processing technique, The proposed algorithm is tested on 30 retinal images where all spot lesions are hand-labeled for performance evaluation. Compared with two existing algorithms, the proposed one significantly improves the overall performance of spot lesion detection producing higher sensitivity and/or predictive values.[2] propose a new constraint for optic disk detection where first detect the major blood vessels and use the intersection of these to find the approximate location of the optic disk. This is further localized using color properties. also show that many of the features such as the blood vessels, exudates and Microaneurysms and hemorrhages can be detected quite accurately using different morphological operations applied appropriately. Extensive evaluation of the algorithm on a database of 516 images with varied contrast, illumination and disease stages yields 97.1% success rate for optic disk localization, a sensitivity and specificity of 95.7% and 94.2% respectively for exudate detection and 95.1% and 90.5% for microaneurysm/ hemorrhage detection.[3] describe a method for automatically detecting new vessels on the optic disc using retinal photography. Vessel-like candidate segments are first detected using a method based on watershed lines and ridge strength measurement. Fifteen feature parameters, associated with shape, position, orientation, brightness, contrast and line density are calculated for each candidate segment. Based on these features, each segment is categorized as normal or abnormal using a support vector machine (SVM) classifier. The system was trained and tested by cross-validation using 38 images with new vessels and 71 normal images from two diabetic retinal screening centers and one hospital eye clinic.[4] propose a combination of internal components of microaneurysm detectors, namely preprocessing methods and candidate extractors.[5] The visual words dictionary was applied to classifying bright and red lesions with classical cross validation and cross dataset validation to indicate the robustness of this approach. We obtained an area under the curve (AUC) of

95.3% for white lesion detection and an AUC of 93.3% for red lesion detection using fivefold cross validation and our

own data consisting of 687 images of normal retinæ, 245 images with bright lesions, 191 with red lesions, and 109 with signs of both bright and red lesions. For cross dataset analysis, the visual dictionary also achieves compelling results using our images as the training set and the RetiDB and Messidor images as test sets.[6] Most of the existing methods of hemorrhage detection can be divided into two consequent stages: red lesion candidate extraction and classification.[7] Morphological Processing is widely used for extracting the diabetic retinopathy lesions. development of an automatic fundus image processing and analytic system to facilitate diagnosis of the ophthalmologists. Color fundus photographs are useful to detect hemorrhages and microaneurysms, hard exudates, and cotton-wool spots. Digital image processing technique (DIP) involves the modification of digital data. This can recover the image clarity, sharpness & details of features of interest towards the information extract & further analysis with the help of computer.[9] Early microaneurysm detection can help reduce the incidence of blindness. Here, we have discussed a method for the automatic detection of Diabetic Retinopathy (ADDR) in color fundus images. Different preprocessing, feature extraction and classification algorithms are used. The performance of the automated system is assessed based on Sensitivity and Specificity. The Sensitivity and Specificity of this approach are 94.44 % and 87.5 %, respectively.[10]

In the above paper, there are some image processing techniques were used for the detection of diabetic retinopathy diseases like Microaneurysms, Exudates, cotton wool spot, and Hemorrhages, and also use some classifiers to classify this diseases with the help of neural network and its sub domains like support vector machine, receiver operating characteristic curve, KNN classifier, Bayesian classifier and so many.

### III. COMPARATIVE ANALYSIS

For detection of diabetic retinopathy disease there are some techniques used by authors and also some authors discussed about the preprocessing of fundus images, most of the papers used the green channel for preprocessing because green channel shows the high intensity range as compare to red, green and blue respectively. And also for detection of lesions used morphological open function, morphological close, morphological remove, morphological Skeletonization are used. For performing the image processing techniques authors used some fundus databases like STARE, DRIVE, DIARETDB0, DIARETDB1, Messidor and own database is used . STARE, DRIVE, DIARETDB0, DIARETDB1, Messidor are online database for fundus images with normal and lesions.

The following table shows the comparative analysis for detection of diabetic retinopathy lesion using image processing techniques and also it has list of databases and classifiers

**Table 2: Techniques used for Detection of Diabetic Retinopathy lesion**

Sr No	Name of Techniques for detection of DR Lesion	Database	Classifier	Result
1	Shape estimation, morphological processing technique	Own database	Statistical classifiers, a Bayesian, a Mahalanobis, and a KNN classifier, Receiver operating characteristic curve	80%
2	unique adaptive multiscale morphological processing technique	Clemson University	Receiver operating characteristic curve	----
3	watershed lines and ridge strength measurement, Morphological processing techniques	Own Database	Receiver operating characteristic curve	95.1%
4	watershed lines and ridge strength measurement, Morphological processing techniques	Own database	Support Vector Machine	91%
5	Morphological preprocessing methods and candidate extractors	Messidor database	Receiver operating characteristic curve	90%
6	Red lesion detection using fivefold cross validation	RetiDB and Messidor	Receiver operating characteristic curve	93.3%
7	Red lesion candidate extraction	STARE, DIARETDBO, and DIARETDBI	Support Vector Machine	-----
8	Morphological Processing	DIARETDBI	Receiver operating characteristic curve	94.44 %

From the above table we come to know that the morphological processing and Watershed is widely used for processing the image and for classing, Receiver operating characteristic is used in most of the papers.

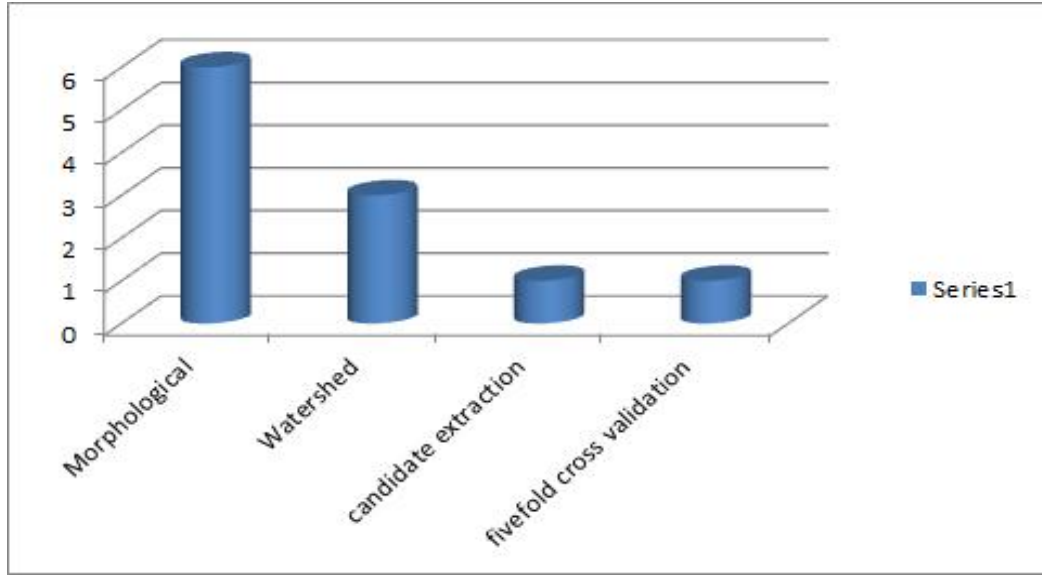


Fig1. Techniques

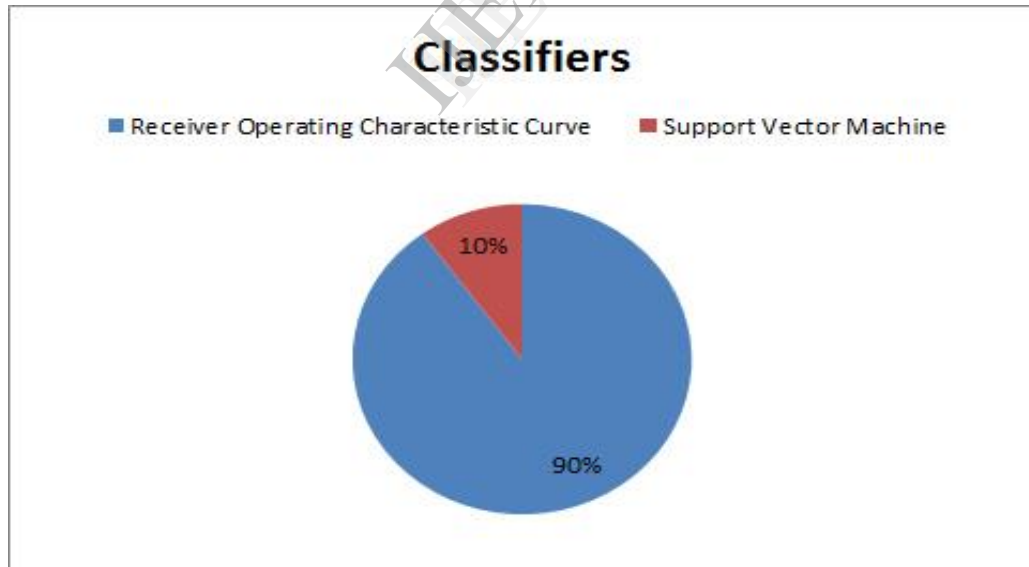


Fig2. Classifiers

#### IV. CONCLUSION

Diabetic retinopathy, is retinopathy (damage to the retina) caused by complications of diabetes, which can eventually lead to blindness. It is an ocular manifestation of diabetes, a systemic disease, which affects up to 80 percent of all patients who have had diabetes for 10 years or more. Despite these intimidating statistics, research indicates that at least 90% of these new cases could be reduced if there was proper and vigilant treatment and monitoring of the eyes. To detect the diabetic retinopathy diseases, some authors used some image processing techniques and classifier, for detecting the lesion Morphological processing is widely used at the same time for classification receiver operating characteristic is used in most of the research papers.

#### REFERENCES

- [1] Bernhard M. Ege, et al, "Screening for diabetic retinopathy using computer based image analysis and statistical classification" Elsevier, Computer Methods and Programs in Biomedicine 62 (2000) 165–175.
- [2] Xin Zhang and Guoliang Fan, "Retinal Spot Lesion Detection Using Adaptive Multiscale Morphological Processing", Springer-Verlag Berlin Heidelberg 2006, ISVC 2006, LNCS 4292, pp. 490–501, 2006.
- [3] Saiprasad Ravishankar, et al, "Automated Feature Extraction for Early Detection of Diabetic Retinopathy in Fundus Images", 978-1-4244-3991-1, 2009 IEEE.
- [4] Keith A. Goatman, et al, "Detection of New Vessels on the Optic Disc Using Retinal Photographs", IEEE transactions on medical imaging, vol. 30, no. 4, april 2011
- [5] B'álint Antal, et al, "An Ensemble-Based System for Microaneurysm Detection and Diabetic Retinopathy Grading", IEEE transactions on biomedical engineering, vol. 59, no. 6, june 2012.
- [6] Anderson Rocha, "Points of Interest and Visual Dictionaries for Automatic Retinal Lesion Detection", IEEE transactions on biomedical engineering, vol. 59, no. 8, august 2012.
- [7] Parisut Jitpakdee, et al, "A Survey on Hemorrhage Detection in Diabetic Retinopathy Retinal Images", IEEE 2012, 978-1-4673-2025-2.
- [8] Arti Yerolkar, Swati Madhe, "Blood Vessel Segmentation and Classification of Retinal Image for Detection of Proliferative Diabetic Retinopathy".
- [9] Jyoti D. Patil, Anant. L. Chaudhari, " Tool for the Detection of Diabetic Retinopathy using Image Enhancement Method in DIP", International Journal of Applied Information Systems (IJ AIS), Volume3, No3., 2012 – ISSN : 2249-0868.
- [10] Sujith Kumar S B, Vipula Singh, " Automatic Detection of Diabetic Retinopathy in Non-dilated RGB Retinal Fundus Images", International Journal of Computer Applications (0975 – 888), Volume 47– No.19, 2012.
- [11] For Diabetic Retinopathy Lesion table <http://www.kellogg.umich.edu/theeyeshaveit/optic-fundus/yellow-white.html>